



Computed Tomography Findings Amongst Adult Patients for Paranasal Sinuses in a Teaching Hospital in North West Nigeria

Abubakar Umar^{1*}; Yaroko A Ango²; Kalu Ochie³; Ishaq Muhammad Nura¹; Sadiq Abubakar Audu¹; Mohammed Abacha¹; Mohammed Dahiru¹; Ilyas Izge Yusuf¹; Aminu Dahiru Guram¹

¹Department of Radiography, College of Health Sciences, Usmanu Danfodiyo University Sokoto, Nigeria.

²Department of Ear, Nose and Throat, Usmanu Danfodiyo University Teaching Hospital Sokoto, Nigeria

³Department of Medical Radiography, Faculty of Allied Health Sciences, Evangel University, Ebonyi State.

*Corresponding Author(s): Umar Abubakar

Department of Radiography, College of Health Sciences,
Usmanu Danfodiyo University Sokoto, Nigeria.

Tel: +2348062847518;

Email: umar.abubakar5@udusok.edu.ng

Abstract

Objectives: To determine the Computed Tomography findings in adult patients for paranasal sinuses and to determine age and gender distributions of the findings.

Method: A convenience sampling was conducted, 159 CT reports of patients with the age range of 11-80 year, that underwent paranasal sinuses examinations were reviewed retrospectively.

Results: Result shows that Rhinosinusitis was the most common computed tomography finding in paranasal sinuses (65; 40.88%) followed by Sinonasal mass 48(30.19%) with patients among the age group of 31-40 mostly affected.

Conclusion: Computed tomography is a valuable radiographic examination for the evaluation of paranasalsinuses. Rhinosinusitis was the most common finding in paranasal sinuses and has no age limit.

Received: Apr 06, 2023

Accepted: May 12, 2023

Published Online: May 18, 2023

Journal: Journal of Radiology and Medical Imaging

Publisher: MedDocs Publishers LLC

Online edition: <http://meddocsonline.org/>

Copyright: © Abubakar U (2023). *This Article is distributed under the terms of Creative Commons Attribution 4.0 International License*

Keywords: Computed tomography; Paranasal sinuses; Rhinosinusitis.

Introduction

Paranasal sinuses are air filled cavities found within the cranial and facial bones. These sinuses include; frontal, ethmoidal, sphenoidal and maxillary sinuses which are connected to the nasal cavity. They are all lined by a pseudo stratified ciliated columnar epithelium containing goblet cells [1]. A Paranasal Sinus (PNS) pathology is one of the commonest reasons for an individual to seek medical care[2].This condition arises from reactive agents such as allergy and infective agents such as viruses, bacteria and fungi [3]. The causative agents of PNS pathologies

can be categorized into allergic infective and non-allergic non infective groups. The inflammatory disease of the PNS lasting less than eight weeks is referred to as acute rhinosinusitis and longer than eight weeks as chronic rhinosinusitis[4].The extents of the pathologies in the nose and paranasal sinuses with their surrounding organ can be determined by appropriate imaging such as plain x ray, computed tomography and magnetic resonance imaging, but computed tomography scan which is regard as goal standard due to its high sensitivity in detecting opacification of paranasal sinuses and bony details [5]. Early diagnosis and appropriate treatment often lead to good outcome, howev-



Cite this article: Umar A, Ango YA, Ochie K, Nura IM, Audu SA, et al. Computed Tomography Findings Amongst Adult Patients for Paranasal Sinuses in a Teaching Hospital in North West Nigeria. J Radiol Med Imaging. 2023; 6(1): 1090.

er, late presentation and disease progression is associated with complications, computed tomography scan is not readily available and when available it is expensive to afford [6]. Plain radiographs depict pathologies associated with mucosal thickening, presence of air-fluid level and partial or complete opacification of the affected sinuses [7]. The main shortcoming of plain radiographs is that they have a high percentage of false negative (<20) and false positive (<25%) results compared to computed tomography of paranasal sinuses [8]. Computed tomography is gradually becoming the first line diagnostic tool for suspected PNS pathologies in northwestern Nigeria as scanners are becoming increasingly available.

Materials and Methods

A retrospective descriptive study design was used for the study. A secondary data source was adopted which was recorded using data capture sheet. The data were obtained from the archives of Radiology Department of Usmanu Danfodiyo University Teaching Hospital (UDUTH). The data were obtained by examining the CT reports of patients that underwent paranasal sinuses examinations for suspected PNS pathology from January 2017 to September 2019. The CT scanner used to examine the patients was a 4-slice GE Bright speed scanner with model: 2335179-2, manufactured in September 2007 by General Electric. One hundred and fifty-nine reports were evaluated and the information such as; age of the patient, sex, date of the examination, provisional diagnosis and corresponding CT findings were recorded. The study adopted Taro Yamane’s formula for sample size determination which was 159. A convenient sampling technique (records evaluated) was used. Data was analysed using descriptive statistics mainly percentages and the data were presented using Tables, bar and pie charts.

Results

The results of statistical analysis of available data collected from one hundred and fifty-nine (159) paranasal sinuses CT reports over a two-year period from January 2017 to September 2019 are presented with the use of tables, charts, pie charts, bar charts, simple percentage and inferential statistics. Out of 159 paranasal sinuses reports, 86 (54.02%) were males and 73 (45.92%) were females. Their age range was 11-80 years. Table 4.1 shows the age distribution of patients and their frequencies and percentage. The age range of 21-30 had the highest frequency (25.16%), followed by the 31-40 age group having (24.53%). The 61-70 and 71-80 age group however had equal low frequency of (3.77%). From the 159 paranasal sinuses CT report evaluated, rhinosinusitis (41%) was the commonest CT finding, followed by sinonasal mass (30%) in and rhinitis (13%) with sinusitis (12%) and normal being the least findings having (4%) as shown in **Figure 4.1**.

Table 4.2 shows clinical presentation of patients in frequency, nasal obstruction (68) is most frequent followed by nasal discharge (29) and halitosis (5) being the least. Gender distribution of paranasal sinuses among the different findings is represented in **Figure 4.2**. The highest frequency was seen under 21-30 age group in both males and females (40;25.16%) having equal male and female frequency, followed by the 31-40 age group (39;24.53%) with females having higher frequency than males. Rhinosinusitis is higher in males and age group of 61-70/71-80 had the least and equal frequency of (6;3.77%) each followed by normal finding having equal male and female percentage 3(50%).

Figure 4.3 Gender distribution of paranasal sinuses frequency and percentage in relation to CT findings showing rhinosinusitis was the commonest CT finding in 65(40.98%) with males 36(55%) having higher frequency than females 29(45%) followed by sinonasal mass 48 (30.19%) with males 29(60%) having higher frequency than females19(40%) and rhinitis 21(13.21%) with sinusitis 19 (11.95%) and normal being the least findings with 6 (3.77%) with equal male and female percentage 3(50%).

Table 1.1: Age distribution of the patients according to age and sex.

Age	Frequency.	Age group
13.21	21	Nov-20
25.16	40	21-30
24.53	39	31-40
15.09	24	41-50
14.47	23	51-60
3.77	6	61-70
3.77	6	71-80
100	159	Total

Table 4.2: Clinical presentation for paranasal sinuses subjects.

Frequency	Clinical presentation
68	Nasal obstruction
10	Rhinorrhoea
15	Nasal swelling
7	Tumor
5	Halitosis
29	Nasal discharge
12	Epistaxis
13	Trismus
159	Total

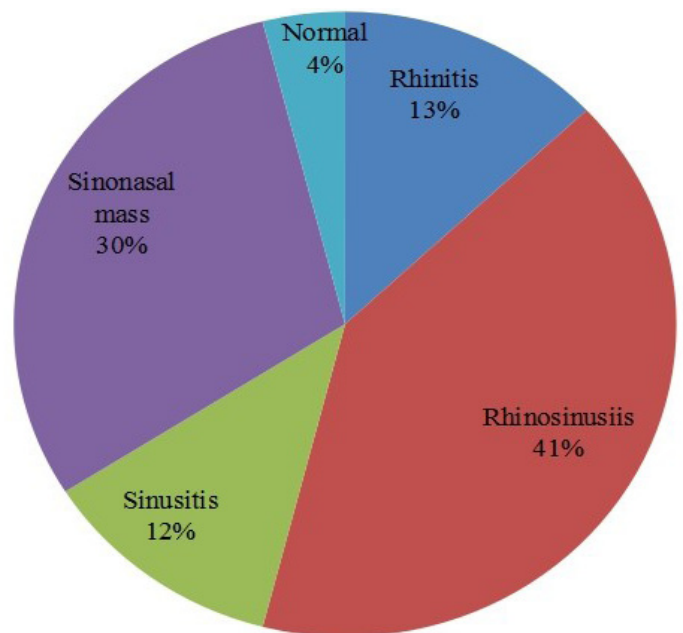


Table 4.1: Distribution of computed tomographic findings in paranasal sinuses.

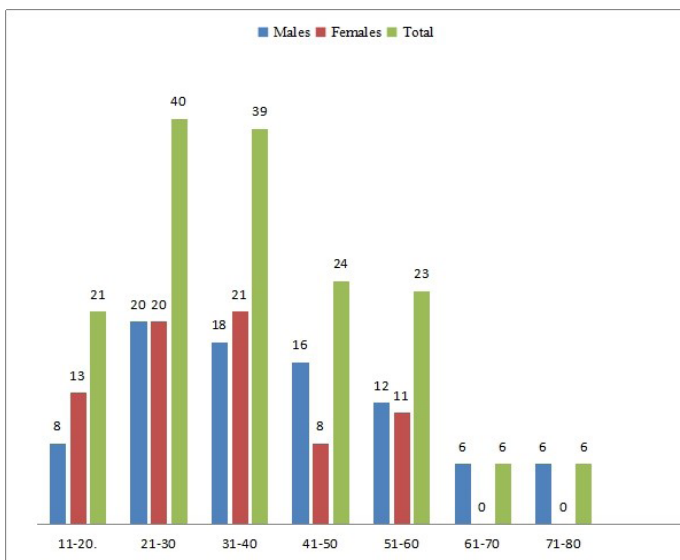


Table 4.2: Gender distribution of paranasal sinuses findings in relation to the age.

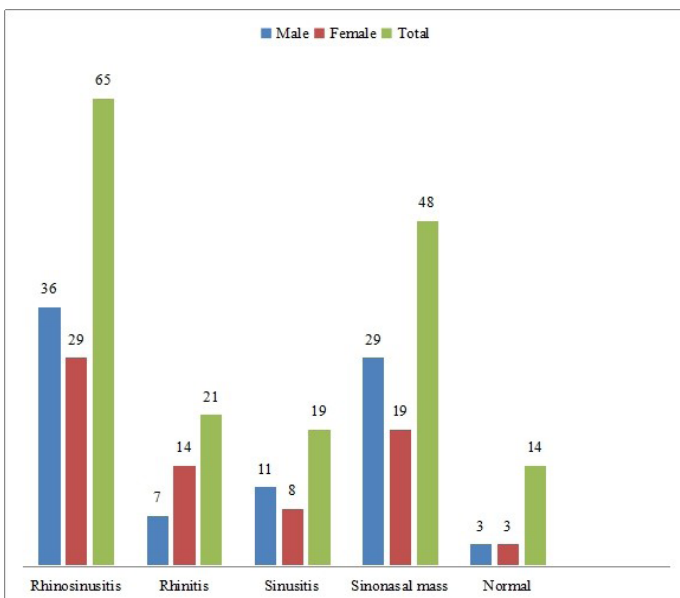


Table 4.3: Shows gender distribution of paranasal sinuses in relation to CT findings.

Discussion

Plain radiography is a first line of radiological examination used in evaluation of paranasal sinuses, although, it is of low sensitivity. This is due to the fact that, computed tomography has high sensitivity in detecting paranasal pathologies, computed tomography can depict pathologies associated with paranasal sinuses and also presence of bony involvement, destruction, mucosal thickening and presence and extent of mass as also reported by [9].

Out of 159 paranasal sinuses evaluated, rhinosinusitis was the most common finding (65; 40.88%). This agrees to CT finding obtained by [10] where they concluded that allergic chronic rhinosinusitis was the commonest type of rhinosinusitis found among adult patients. Likewise, sinonasal tumor 48 (30.19%) being the second most common CT finding was also similar to study by Vermaet *al.*, in which main presenting complaints were nasal obstruction (82%) followed by nasal discharge (66%), headache and allergic symptoms (52%) which is also similar to this study [11]. The most common type of disease involving nose and paranasal sinuses was inflammatory disease (86%) followed

by benign disease (10%) and malignant disease were found in (4%) of cases. The most common benign disease involving nose and paranasal sinuses is inverted papilloma. This identified the role of computed tomography imaging in the evaluation of paranasal sinuses diseases, Inflammatory diseases were the most prevalent (86.0%) which is similar to what was observed in this study. The inflammatory findings in this study were rhinosinusitis (40.98%), rhinitis (13.21%) and sinusitis (11.95%) as shown in Figure 4.2. in which the age distribution of the findings showed that, 21-30 age group have the highest frequency (40; 25.16%) which is similar with the finding obtained by Hussein *et al.*, [12] which was 19-29 years and similar to study by Abubakar *et al.*, with age group 24-33 mostly affected. Ugwuanyi *et al.*, found out males (74%) were more affected than females (26%). This is similar to the finding in this study as males were seen to be more affected 54 (54.02%) than females 46 (45.92%).

Sinusitis 19 (11.95%) and normal findings being the least findings with 4 (3.77%), this is in line with the study conducted by Umar *et al.*, (2018) as sinusitis and normal findings being the least of the findings 5(5.85%).

Summary and Conclusion of Findings

1. Rhinosinusitis was the most common CT finding in paranasal sinuses.
2. Males were more affected by paranasal sinuses diseases.
3. 21-30 age groups had the highest frequency of paranasal sinuses diseases.

From the result of this studies of computed tomography examination for the evaluation of paranasal sinuses, rhinosinusitis was the most common followed by sinonasal mass finding in paranasal sinuses in this environment.

References

1. Cormack DH. Essential Histology, 2nd ed. Philadelphia: Lippincott William &Wilkins. 2001; 337-340.
2. Benniger MS, Micheal G. George, Martin GB, Ray JB, Nicholas CH, et al. Scott Brown’s otorhinolaryngology, head and neck surgery, 7th ed. 3. London NW13BH; Edward Arnold Ltd. 2008; 3351-3358.
3. Chandramani P, Ashok S. Allergic Aspergillus Sinusitis and its association with Allergic Broncho-pulmonary Aspergillosis. Asian Pacific Allergy. 2011; 1: 130-137.
4. David Albert, Alan G, Kerr John B. Booth Scott-Brown Browns. Otolaryngology 6th ed. Oxford Ox2 8DP. Reed educational and professional publishing Ltd. 1997.
5. Kolo ES. The role of plain radiographs in the diagnosis of chronic maxillary rhinosinusitis in adult. African Health Sciences. 2012; 12: 459-463.
6. Sogebi O, Oyewole E. Rhinosinusitis ; clinical features seen in Sagamu, Nigeria. Internet scientific publication. The internet Journal of otolaryngology. 2006; 6: 1-4.
7. Abubakar U, Yaroko AA, Muhammad A. Sadiq, Akpaniwo AA, Muhammad GM, et al. Common X-ray findings for paranasal sinuses and postnasal space in two hospitals in Sokoto. Nigerian Journal of Medical Imaging and Radiation Therapy. 2018; 8: 1-3.
8. Marchie TT. Comparative evaluation of plain radiological findings and computerised axial tomographic seen findings in evaluation of paranasal sinuses and mastoid air cells Nigerian Journal of Clinical Practice. 2001; 4: 22-24.

-
9. Ugwuanyi Daniel C, Chiegwu Hyacinth U, Anakwue Angel Mary C, Ajekwuelu Emmanuel O, Balagun Oluwatoyin B. Prevalence of paranasal air sinusitis Computed tomographic findings in a tertiary hospital south east Nigeria. GJRA. 2018; 7: 2277-8160.
 10. Onotae L and Oparaodu O. Rhinosinusitis in Adult Patients: Analysis of clinical pattern and outcome of management, Gazette of Medicine. 2016; 5: 1-15.
 11. Verma J, Kumar RS, Mishra S, Mishra AK. The role of diagnostic imaging in evaluation of nasal and paranasal sinus pathologies. International Journal of Otorhinolaryngology and Head and neck surgery. 2016; 2: 140-146.
 12. Husasein AO, Ahmad BH, Ali MA, Manafal MF, Elhy AB. Assessment of Clinical, X-Ray and CT in Diagnosis of Paranasal Sinus Diseases. International journal of science and research. 2014; 6: 7-11.